

## ASTHMA MIMICS (ACUTE RESPIRATORY FAILURE CAUSED BY GIANT RETROSTERNAL NONTOXIC GOITER)

Hussam Eddin Badi<sup>1</sup>, Mohammed Traina<sup>2</sup>, Masoud Ghazit<sup>2</sup>, Esmail Alghanudi<sup>2</sup>

1- Surgical department, Misurata Central Hospital

2- Medical department, Misurata Central Hospital

### Summary

A 70 years old Libyan lady complaining of dyspnea and was treated as bronchial asthma for 3 years. She was admitted to the medical ward; as her condition worsened recently; where she re-evaluated and diagnosed as acute respiratory failure caused by giant retrosternal nontoxic goiter.

### INTRODUCTION

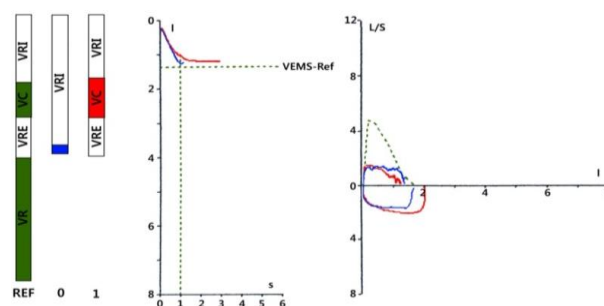
Retrosternal goiter (RSG) is defined as a goiter in which the thyroid mass has descended the plane of the thoracic inlet or if more than 50% of the thyroid mass is located below the thoracic inlet. Due to the variety of definitions the percentage of RSG varies from 2% to 20% of all patients undergoing thyroidectomy<sup>(1,2)</sup>. It accounts for 3-12% of mediastinal masses<sup>(3)</sup>. The symptoms are usually caused by compression of the adjacent structures including the trachea, esophagus, and superior vena cava<sup>(1,4,5)</sup>. This condition has a clinical importance as it presents a diagnostic dilemma with its compressive symptoms and operative difficulty.

### CASE REPORT

A 70 years old lady was presented to the emergency room complaining of shortness of breath. She had any difficulty in breathing for 3 years and was diagnosed and treated previously as a bronchial asthma. She did not improve with medications and began to experience orthopnea and referred for admission to the medical ward for further management. She had been investigated by spirometer as part of work up for bronchial asthma. She did not notice any swelling in the neck and not show symptoms of hypo or hyperthyroidism. On examination she was dyspneic, tachypneic and orthopneic, with blood pressure of 200/100 mmHg, visible JVP pulse and audible stridor. However, there was a small diffused swelling in the anterior aspect of the neck which moved with swallowing. The trachea was shifted to the right side. By percussion, there was dullness over the sternum and all laboratory parameters were within normal limits. Furthermore; flow-volume loops revealed flattened top and bottom loops so that configuration approaches that of rectangle which indicates a fixed obstruction of upper airway as shown in (figure 1).

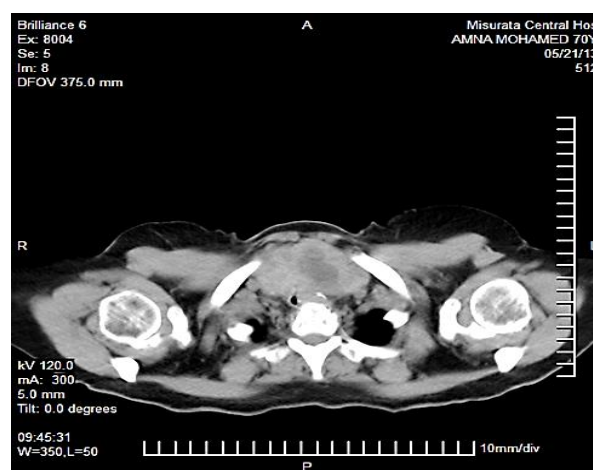
Ultrasound and CT scan of the neck revealing a retrosternal mass, that showed the thyroid gland as a large heterogeneous ill-defined multinodular lesion meas-

ured  $\approx 92 \times 60 \times 40$  mm with mixed density due to calcification and necrosis.



(Figure 1) flow-volume loops

The lesion causes compression of the trachea and right shift, with retrosternal extension that reach up to level of T3 vertebrae as shown in (figure 2). Fine needle aspiration cytology revealed a follicular adenoma.



(Figure 2-a)

A significant variability regarding the clinical presentation and the surgical management of RSG has found during review of literature which can be explained to some extent by the different definitions employed. RSG is classified as primary accounting for less than 1% and derive from ectopic thyroid tissue in the mediastinum<sup>(1,4)</sup>; or secondary RSG which account for 99% it is characterized by the downward growth of cervical thyroid tissue into the thoracic inlet<sup>(1,4)</sup>, and continue

Received 22/4/2015 ; Accepted 10/5/2015

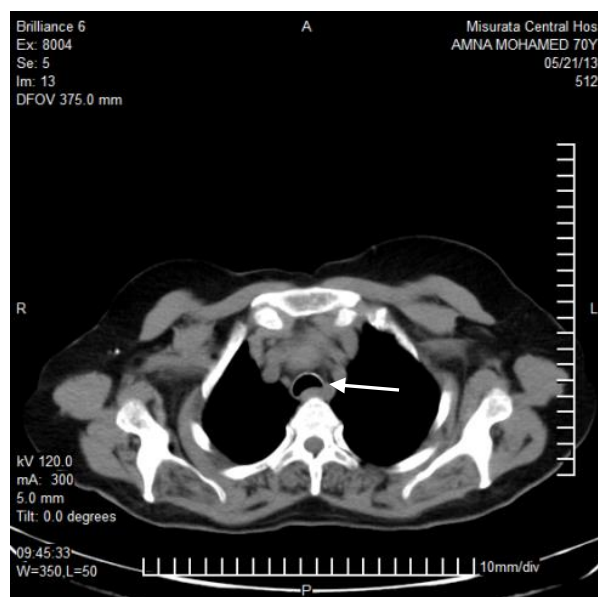
Correspondence and reprint request :

Hussam Eddin Badi

Surgical department

Email : hussambadi@yahoo.com

to receive blood supply from the superior and inferior thyroid arteries<sup>(1)</sup>.



(Figure 2-b)

(Figure 2) CT scan of neck (arrow indicates compressed deviated trachea)

### DISCUSSION

Majority of these goiters (85 - 90%) are mostly situated in the anterior mediastinum, and can be unilateral or bilateral, growing cross the midline, the others are located in the posterior mediastinum<sup>(1,2,4)</sup>. Patients with RSG are generally presented in their fifth and sixth decades of life and have a female predominance; female/male ratio 3:1<sup>(1,6)</sup>. While 15 to 50% of patients are asymptomatic<sup>(6)</sup>. The most important presented symptoms result from mediastinal compression<sup>(7)</sup> and especially from tracheal compression. The majority of them (68.8%) present with dyspnea or asthma like symptoms as was the presented case. Patients may also present by neck mass (75%), hoarseness of voice (37.5%), dysphagia (31.3%), stridor/wheezing 19%, or superior vena cava obstruction (6.25%)<sup>(8)</sup>. It is reported that up to (25 - 33%) of patients with giant goiters have upper airway obstruction symptoms, and (10%) of these patients require emergency airway intubation<sup>(9)</sup>. In fact that, the upper airway obstruction indicating prompt intervention for an enlarged thyroid gland is rare condition; the incidence of benign nodular goiters causing upper airway obstruction is not well defined varying between 0.8% and 31% in different studies<sup>(10,11)</sup>. It was suggested that several reasons have been responsible for the acute obstruction of the upper airway in benign nodular goiter. Additionally; retrosternal localization of the enlarged gland in relatively small space is mostly associated with tracheal compression and displacement, leading to varying degrees of dyspnea. It predisposes, but does not cause, obstruction and the exact cause of obstruction in such patient who already has a compressed airway is not clear. Upper respiratory tract infections, chronic ob-

structive pulmonary disease, and bleeding into a cystic component of the enlarged gland might have contributed to this acute event<sup>(12)</sup>. It is also reported that recognizable changes in lung function occur when the cross-sectional area of the airway has been reduced by more than 50%<sup>(10)</sup>. In fact, despite these contributing factors, they thought that the main reason for the acute presentation is the time delay between diagnosis and operation<sup>(12)</sup>. This impairment can easily develop into upper airway obstruction when these factors are considered. The differential diagnosis of acute dyspnea and upper airway obstruction must be considered including bronchial carcinoma, thymomas, dermoid cysts, or lymphomas. Similarly to the presented case Nandwani et al. reported a case in which upper airway obstruction and dyspnea were confused with asthma, they used a flow-volume loop serving to aid in the diagnosis and monitoring of suspected airway obstruction<sup>(13)</sup>. Similar findings were reported by Thusoo et al. who support the idea that flow-volume loops provide an added advantage over conventional radiology alone in the detection of upper airway obstruction<sup>(14)</sup>. CT scan was considered the gold-standard preoperative radiological investigation<sup>(15)</sup>. As it more clearly demonstrated the tracheal obstruction and retrosternal component; CT scan also provides more information for the differential diagnosis of mediastinal masses that can also cause upper airway obstruction<sup>(16)</sup>. On the other hand; the standard post-anterior and lateral chest X-rays are considered the most single valuable diagnostic tools with regard to the study of intrathoracic goiters as these radiographs can provide valuable information about the compression of the trachea<sup>(17)</sup>. Surgical treatment is indicated for RSG causing upper airway obstruction; this was the case as the studied patient had total thyroidectomy through collar incision. Post-operative our patient was in good general health, without any respiratory symptom after cessation of all anti-asthma treatment which she was receiving for 3 years.

### CONCLUSION

Prognosis in RSG is very good if diagnosed and treated in the proper time.

### REFERENCES

- 1- White ML, Doherty GM, Gauger PG. Evidence-based surgical management of substernal goiter. *World J Surg.* 2008; 32:1285-300.
- 2- Agha A, Glockzin G, Ghali N, Iesalnieks I, Schlitt HJ. Surgical treatment of substernal goiter: an analysis of 59 patients. *Surg Today.* 2008; 38:505-11.
- 3- Vadasz P, Kotsis L. Surgical aspects of 175 mediastinal goiters. *Eur J Cardio- Thoracic Surgery* 1998; 14:393-397.
- 4- Ket S, Ozbudak O, Ozdemir T, Dertsiz L. Acute respiratory failure and tracheal obstruction in patients with posterior giant mediastinal (intrathoracic) goiter. *Interact Cardiovasc Thorac Surg.* 2004; 3:174-5.
- 5- Hunis CT, Gerogalas C, Mehrzad H, Tolley NS. A new classification system for retrosternal goiter based

on a systemic review of its complications and management. *Int J Surg* 2008; 6:71-76.

6- Cagli K, Ulas MM, Hizarci M, Sener E. Substernal goiter: an unusual cause of respiratory failure after coronary artery bypass grafting. *Tex Heart Inst J*. 2005; 32:224-7.

7- Darwish BK, Kabbani SS. Giant substernal goiter with chylothorax. *Asian Cardiovasc Thorac Ann*. 2003; 11:165-6.

8- Moran JC, Singer JA, Sardi A. Retrosternal goiter: A six-year institutional review. *Am Surg* 1998; 64: 889-893.

9- Shaha AR, Burnett C, Alfonso A, Jaffe BM. Goiters and airway problems. *Am J Surg* 1989; 158: 378-80.

10- Bright P, Miller MR, Franklyn JA, Sheppard MC. The use of a neural network to detect upper airway obstruction caused by goiter. *Am J Respir Crit Care Med* 1998; 157: 1885-91.

11- Miller MR, Pincock AC, Oates GD, Wilkinson R, Skene-Smith H. Upper airway obstruction due to goitre: detection, prevalence and results of surgical management. *Q J Med* 1990; 74: 177-88.

12- Başoğlu M, Öztürk G, Aydın B, Yıldırğan Mİ, Atamanalp SS, Celebi F. Benign Nodular Goiter Causing Upper Airway Obstruction. *Eurasian J Med*. 2009 Aug;41(2):75-9.

13- Nandwani N, Tidmarsh M, May AE. Retrosternal goiter: a cause of dyspnoea in pregnancy. *Int J Obstet Anesth* 1998; 7: 46-9.

14- Thusoo TK, Gupta U, Kochhar K, Hira HS. Upper airway obstruction in patients with goiter studies by flow volume loops and effect of thyroidectomy. *World J Surg* 2000; 24: 1570- 2.

15- Grainger J, Saravanappa N, D'Souza A, Wilcock D, Wilson PS. The surgical approach to retrosternal goiters: the role of computerized tomography. *Otolaryngol Head Neck Surg* 2005 Jun; 132(6): 849-851.

16- Cagli K, Ulas MM, Hizarci M, Sener E. Substernal goiter: an unusual cause of respiratory failure after coronary artery bypass grafting. *Tex Heart Inst J* 2005; 32: 224-7.

17- Bizakis J, Karatzanis A, Hajioannou J, et al. Diagnosis and management of substernal goiter at the University of Crete. *Surg Today* 2008; 38: 99-103.